
A randomized double-blind placebo-controlled pilot study to assess the efficacy of a 24-week topical treatment by latanoprost 0.1% on hair growth and pigmentation in healthy volunteers with androgenetic alopecia

Ulrike Blume-Peytavi, MD, Sanna Lönnfors, MScPH, Kathrin Hillmann, MD, and
Natalie Garcia Bartels, MD
Berlin, Germany

Background: Latanoprost is a prostaglandin analogue used to treat glaucoma. It can cause adverse effects, such as iridial and periocular hyperpigmentation, and eyelash changes including pigmentation and increased thickness, length, and number. Latanoprost has been used to treat eyelash alopecia, but knowledge on its effects on human scalp hair growth is not available.

Objective: The primary objectives were to assess the efficacy of latanoprost on hair growth and pigmentation. The secondary objectives were to assess the effect on scalp pigmentation; investigate the treatment duration needed to affect hair growth, hair pigmentation, and scalp pigmentation; and assess safety of latanoprost.

Methods: Sixteen men with mild androgenetic alopecia (Hamilton II-III) were included. Latanoprost 0.1% and placebo were applied daily for 24 weeks on two minizones on the scalp. Measurements on hair growth, density, diameter, pigmentation, and anagen/telogen ratio were performed throughout the study.

Results: At 24 weeks, an increased hair density on the latanoprost-treated site was observed compared with baseline ($n = 16$, $P < .001$) and placebo-treated site ($P = .0004$).

Limitations: Only young men with mild androgenetic alopecia were included. The results may not be applicable to other patient groups. Choice of investigational site may have affected the results.

Conclusions: Latanoprost significantly increased hair density (terminal and vellus hairs) at 24 weeks compared with baseline and the placebo-treated area. Latanoprost could be useful in stimulating hair follicle activity and treating hair loss. (J Am Acad Dermatol 2012;66:794-800.)

Key words: androgenetic alopecia; hair density; hair growth; hair pigmentation; latanoprost; scalp pigmentation.

The prostaglandin F $_{2\alpha}$ analogue latanoprost is widely used in treating open-angle glaucoma and ocular hypertension as ophthalmic solution (0.005%) because of its efficacy and minimal

systemic adverse effects.^{1,2} Latanoprost may induce local adverse effects, eg, iridial and periocular pigmentation,³⁻⁷ erythema, and telangiectasia.⁸ Increased eyelash thickness and length, extra

From the Department of Dermatology and Allergy, Clinical Research Center for Hair and Skin Science, Charité-Universitätsmedizin Berlin.

Supported by a research grant for the L'Oréal Civatte Professorship (Dr Blume-Peytavi).

Conflicts of interest: None declared.

Accepted for publication May 22, 2011.

Reprint requests: Ulrike Blume-Peytavi, MD, Department of Dermatology and Allergy, Clinical Research Center for Hair

and Skin Science, Charité-Universitätsmedizin Berlin, Charitéplatz 1, D-10117 Berlin. E-mail: ulrike.blume-peytavi@charite.de.

Published online August 29, 2011.

0190-9622/\$36.00

© 2011 by the American Academy of Dermatology, Inc.

doi:[10.1016/j.jaad.2011.05.026](https://doi.org/10.1016/j.jaad.2011.05.026)

eyelash rows, conversion of vellus hairs into terminal hairs, pigmentation,⁹ curvature,¹⁰ and eyelash ptosis have also been observed.¹¹

Latanoprost has been used as eye drops to stimulate eyelash growth in alopecia areata. Case reports have documented minimal eyelash growth 3 to 4 weeks and pronounced growth 8 weeks after treatment onset.^{12,13} In all, 17.5% of patients with eyelash alopecia treated with 0.005% latanoprost experienced complete and 27.5% moderate regrowth.¹⁴ To our knowledge, its effect on scalp hair growth has only been tested on animals. Hair regrowth was observed in latanoprost-treated macaque monkeys¹⁵ and latanoprost-treated mice compared with untreated controls.¹⁶

The observations suggest that latanoprost may be used for treating hair loss and canities. As much of the relevant literature appears in ophthalmologic journals, dermatologists may not be familiar with the promising effects.¹⁷ Furthermore, the follicles and growth cycles of scalp hair and eyelashes are not identical.¹⁸ It remains unknown whether latanoprost induces hair growth and pigmentation in intermediate and terminal androgen-dependent hair, and if so, which concentration and treatment duration are necessary.

The main objectives were to assess the efficacy of latanoprost on hair growth and pigmentation. The secondary objectives were to investigate the effect on scalp pigmentation, the treatment duration needed, and the safety of latanoprost. Latanoprost was chosen as a medically licensed representative of prostaglandin F2 α analogues, with the intention to prove the concept that prostaglandins are potential promising agents for influencing hair growth.

METHODS

Study design

This was a monocenter, double-blind, randomized pilot study to assess the efficacy of a 24-week topical treatment with latanoprost 0.1% on hair growth and pigmentation in healthy volunteers. The subjects were randomized on location: each subject applied latanoprost on one investigational site and placebo on the other. The trial was conducted at the Clinical Research Center for Hair and Skin Science at the

Charité-Universitätsmedizin Berlin, Germany, in 2003 in accordance with the Declaration of Helsinki principles, Good Clinical Practices, and local regulatory requirements (No. 1842/Si.260).

Subjects

Subjects were 16 healthy male volunteers, aged 23 to 35 years, with dark blond to light brown hair and of phototype III to IV, presenting a recently developed frontotemporal alopecia (Hamilton stage II-III). After written informed consent, a general clinical examination and an interview on medical history and concomitant therapies were performed. Exclusion criteria included female sex; scalp atrophy and/or canities on frontotemporal regions; any skin affection on the investigational areas; any ophthalmic pathology; allergy or hypersensitivity to any colorant, medicinal product, or component of the investigational

product; a history of skin cancer; acute or chronic illness interfering with the trial conduct; physical treatments on the head within the last 6 months; using depigmenting or propigmenting products on the scalp or head during the last 3 months; planned ultraviolet sessions or sun exposure of the head during the study period; and using topical or systemic drugs or cosmetics that could interfere with the study assessments in the last month.

Investigational products

The investigational product was latanoprost 0.1% ternary solution (50% ethanol, 20% propylene glycol, water) packaged in droppers (flasks), compared with placebo packaged in identical droppers. The dose was considered to pose no risk, being 3.6 times less than the dose reportedly tolerated intravenously. Each subject received both products with the dose of one drop ($\sim 50 \mu\text{L}$) daily for 24 weeks on two symmetric locations on the scalp according to randomization. The first topical application was performed on site by the investigator and for the first 4 weeks, 5 days a week, by a site technician. After ensuring correct application, each subject applied the products at home for the following 20 weeks. At the end drug accountability was performed for controlling compliance and total drug application.

CAPSULE SUMMARY

- When used to treat glaucoma, the prostaglandin analogue latanoprost may cause eyelash changes including pigmentation and increased thickness, length, and number, and has therefore potential to also stimulate scalp hair follicles.
- The effect of latanoprost on human scalp hair growth and pigmentation and the treatment duration needed were assessed in this study.
- Latanoprost increased vellus and terminal hair density and may be useful for stimulating hair follicle activity and treating hair loss.

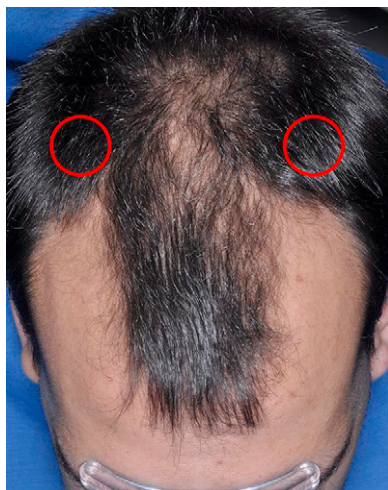

Fig 1. Male subject with androgenetic alopecia (Norwood Hamilton scale grade III). Marked areas indicate minizone position for topical application of latanoprost and placebo solutions.

Technical procedures

A medical examination was performed on the inclusion day to ensure the subject's eligibility, and again at the end of the study.

Two minizones of approximately 3 cm², clinically similar in hair density, pigmentation, and scalp condition and containing dark blond or light brown hair only, were delimited on the left and right frontotemporal regions of the scalp, minimum 8 cm apart (Fig 1). Both minizones received a dot tattoo for identification throughout the study. The surrounding areas were localized throughout the study using a plastic template with the subject's initials and number.

Right/left attribution of the investigational sites was randomized and double blinded. The investigational products were applied daily at the same time directly on the scalp on their respective site and distributed with a fingertip around the tattoo to cover the entire minizone.

Evaluations

The study consisted of 7 assessment periods, each including 2 days, which were 3 days apart (day 1, day 4). The assessments (TrichoScan [Tricholog GmbH, Freiburg, Germany], pigmentation and macrophotographs) were performed before treatment at 4, 8, 12, 16, 20, and 24 weeks.

TrichoScan. TrichoScan (Tricholog GmbH) combines epiluminescence microscopy and digital image analysis to measure hair growth rate, density, diameter, and anagen/telogen ratio. The hair in the investigational site is clipped and the site photographed. Three days later, the clipped hairs are dyed

black to increase contrast. The sites are cleaned with an alcoholic solution and photographed again. The technique is easy to perform, highly validated,¹⁹⁻²¹ noninvasive, and with the exception of the tattoo marking the site, causes no discomfort to the patient.²² Measurements were performed on day 1 (hair diameter) and day 4 (hair density and anagen/telogen ratio) of each assessment period.

Macrophotographs. Standardized photographs and close-ups of each investigational site were performed on day 1 of each assessment period. Each photograph was performed at least twice with a digital camera (Canon D30, Canon Inc, Tokyo, Japan).

Pigmentation. The pigmentation of hair and scalp on both minizones was evaluated visually on day 1 of each assessment period based on the global photographs. Changes on the latanoprost-treated site were rated as slightly, moderately, or significantly darker/lighter or as no change compared with placebo-treated site.

Local intolerance. Local tolerance was evaluated at each assessment period by direct evaluation for erythema and desquamation, and through subject interview for pruritus, burning, or any discomfort.

Clinical evaluation. A clinical evaluation was performed before treatment onset and at 12, 16, 20, and 24 weeks, including the comparison of both minizones 3 days after shaving and before hair coloring for TrichoScan (Tricholog GmbH) analysis.

Global assessment. A global assessment of the investigational sites regarding hair growth (length), density, thickness, and hair and skin pigmentation was performed by the investigator and the subject. This was done at baseline and weeks 12 and 24 by comparing the investigational sites using a specific 7-point scale (clearly/moderately/slightly improved, no changes, slightly/moderately/clearly worsened).

Clinical evaluations

The clinical evaluation to compare the investigational sites was performed before unblinding using the 7-point intensity scale based on 4 criteria: hair length, density, thickness, and pigmentation. Minizones 1 and 2 were changed into "latanoprost" or "placebo" after code unblinding.

TrichoScan data

The parameters measured by TrichoScan (Tricholog GmbH) were hair density (n/0.651 cm²), percentages of anagen hairs (length >0.74 mm 3 days after shaving) and telogen hairs (length unchanged or <0.74 mm after 3 days), and percentages of vellus (diameter ≤ 40 μm) and terminal hairs. All were measured on both investigational sites

throughout the study. The TrichoScan (Tricholog GmbH) images were reviewed by the investigator directly when taking them. Photographs were taken until a clear, sharp image, suitable for analysis, was obtained. Other images were not saved.

Statistical analysis

A two-sample Student *t* test was used for comparisons at baseline and during the study. The tests were interpreted with the risk α of 5%. A 10% threshold was kept to detect tendencies.

RESULTS

The 16 subjects received the investigational products at two minizones, comparable at randomization, on the frontotemporal regions during 24 weeks. The quantitative data at baseline were also comparable as measured by TrichoScan (Tricholog GmbH).

Clinical evaluation

Based on clinical evaluation (hair density, length, thickness, and pigmentation), the subjects were divided into 3 groups:

- 50% good clinical response (8/16) (latanoprost better than placebo at 24 weeks in at least two criteria, or in one criteria already at 12, 16, or 20 weeks).
- 44% no clinical response (7/16) (no differences or inconsistent scores between latanoprost and placebo).
- 6% bad clinical response (1/16) (placebo better than latanoprost at 24 weeks in at least two criteria, or in one criterion already at 12, 16, or 20 weeks).

In the subject responding poorly, hair density increased more at the placebo- than the latanoprost-treated site after 16 and 24 weeks of treatment. Table I presents the response profiles of the participants responding to latanoprost.

With the exception of subject B (visible changes at 24 weeks), all subjects responded to treatment after 12 (*n* = 3) or 16 (*n* = 4) weeks. The first response in most subjects (*n* = 6) was hair density. Effects on thickness, length, and pigmentation appeared later, with the exception of subject F. Fig 2 (TrichoScan [Tricholog GmbH] images of the investigational zones 3 days after shaving) presents the effects of latanoprost on hair growth. Hair pigmentation on the latanoprost-treated site was observed visually in 4 and scalp pigmentation in one participant.

TrichoScan data

All data were validated by the investigator and controlled before statistical analysis. Hair density showed different developments over the 24-week

Table I. Clinical response profiles in subjects responding to latanoprost (*n* = 8)

Subject	12 wk	16 wk	20 wk	24 wk
A	—	L/T/P	L/P	D/L/P
B	—	—	—	D/P
C	—	D	D	D/T/P
D	D	D/L	D	D
F	D/L/T/P	D/L/T/P	D/T/P	D/T/P
I	D	D	—	D
K	—	D	—	D/T
M	—	D	—	D

D, Density; L, length; T, thickness; P, pigmentation; —no success.

treatment period. An increase was observed from 8 weeks onward (+9%, *P* = .03) at the latanoprost-treated site, reaching +22% at 24 weeks (*P* < .001). The variations at the placebo-treated site remained relatively small (+10% at 24 weeks) and statistically insignificant. The investigational sites did not differ at baseline (*P* = .2), however there was a significant difference from 8 weeks of treatment onward (*P* = .03 at 8 weeks, *P* = .004 at 24 weeks).

Hairs in anagen and telogen phase—anagen/telogen ratio

Anagen/telogen hairs (absolute value, percent). TrichoScan (Tricholog GmbH) allows differentiating hairs in anagen (length >0.74 mm, 3 days after shaving) and telogen (length <0.74 mm, 3 days after shaving) phase. Fig 3 shows the hair densities at both sites at baseline and 24 weeks and the division into anagen and telogen in absolute values. A decrease of 5.1% in anagen hairs and increase in the telogen hair percentage were observed at the latanoprost-treated site (*P* = .02). At the placebo-treated site, a decrease of 5.6% in anagen hairs was observed, and conversely, an increase in the telogen hair percentage (*P* = .08). The investigational sites showed no difference at baseline (*P* = .8) or 24 weeks (*P* = .9).

Anagen/telogen ratio. The anagen/telogen ratio decreased from 1.98 to 1.57 (*P* = .03) at the latanoprost-treated site. At the placebo-treated site, the ratio decreased from 2.28 to 1.67 (*P* = .1). The investigational sites showed no difference at baseline (*P* = .5) or 24 weeks (*P* = .6).

Terminal and vellus hairs—terminal/vellus ratio

Terminal/vellus hairs (absolute value, percent). At the latanoprost-treated site, an increase of 3.5% in vellus hairs (diameter ≤40 μm) and a decrease in the terminal hair percentage (diameter >40 μm) were observed (*P* = .05). At the

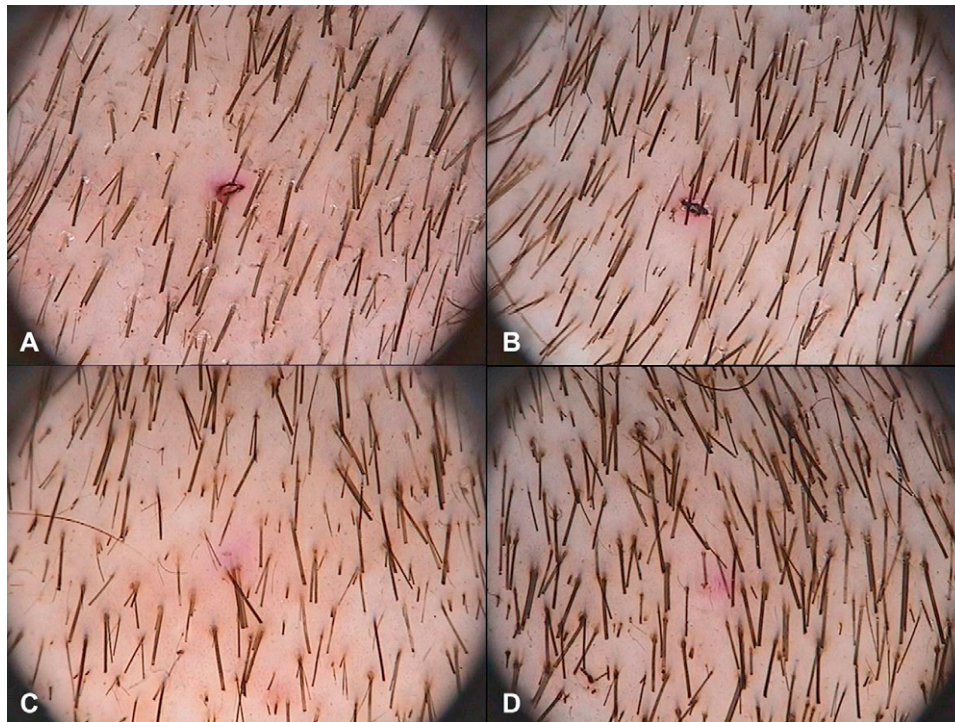


Fig 2. Study areas on participant. Placebo (A) and latanoprost (B) at baseline. Placebo (C) and latanoprost (D) at 24 weeks.

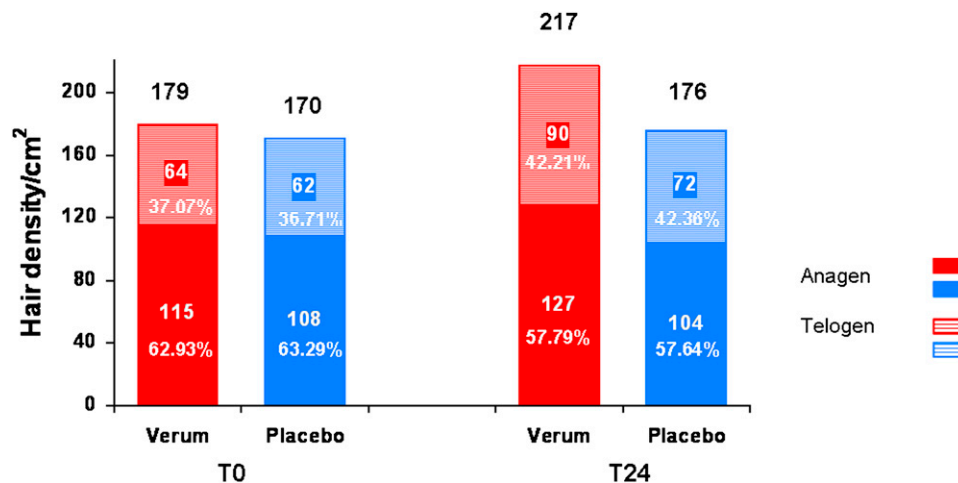


Fig 3. Number and percentage of anagen and telogen hairs/cm² at baseline and 24 weeks.

placebo-treated site, an increase of 1.2% in vellus hairs and a decrease in the terminal hair percentage ($P = .3$) were observed. The investigational sites showed no difference in the vellus and terminal hairs percentages at baseline ($P = .4$) or 24 weeks ($P = .4$) (Fig 4).

Terminal/vellus ratio

At the latanoprost-treated site, the terminal/vellus ratio decreased from 16.26 to 11.28 ($P = .1$) and at the placebo-treated site from 16.77 to 14.35 ($P = .4$).

There was no difference at the investigational sites at baseline ($P = .8$) or 24 weeks ($P = .3$).

The TrichoScan (Tricholog GmbH) analysis confirms that latanoprost significantly increases overall hair density compared with baseline and the placebo-treated area from 8 weeks of treatment onward.

Safety and product acceptability

Adverse events. Eight subjects presented a total of 9 cutaneous adverse effects (Table II). Only the erythematous reactions observed at the

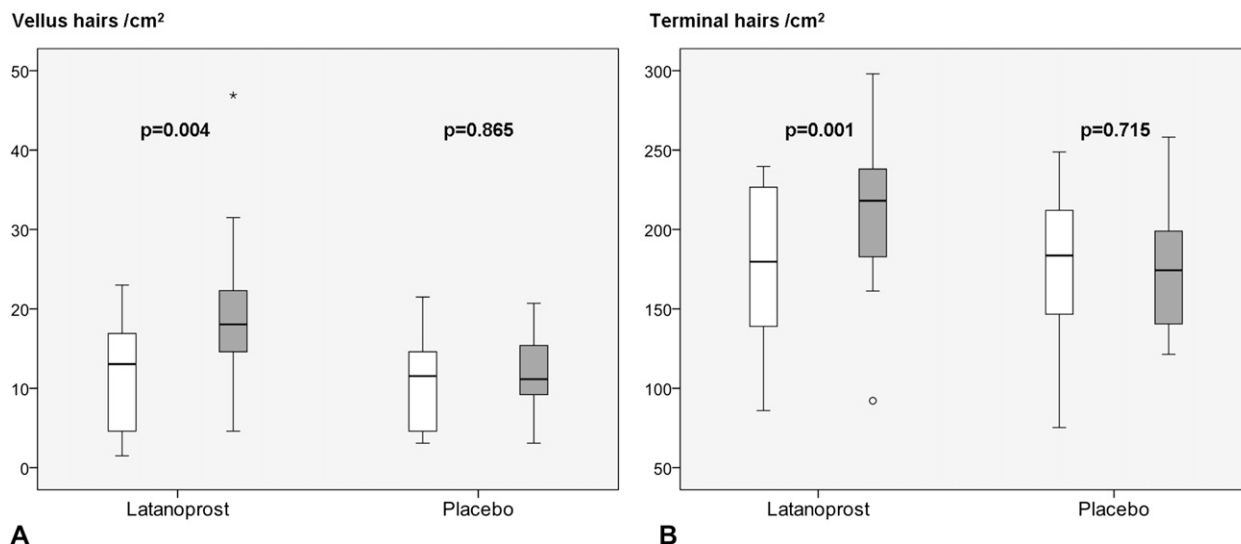


Fig 4. Vellus (**A**) and terminal (**B**) hair density developments on latanoprost- and placebo-treated areas. Both vellus and terminal hair density increased significantly from baseline (*white box*) to 24 weeks (*gray box*) on latanoprost-treated site.

Table II. Adverse effects observed over 24-week study period in all 16 subjects

Subject	Adverse effect	
Located at latanoprost-treated site		
A, B, C, F, M	Erythema	n = 5
E	Folliculitis	n = 1
Located at 2 investigational sites		
F	Sensation of bilateral burning	n = 1
Located outside investigational sites		
G	Erysipelas	n = 1

latanoprost-treated sites are likely to be possibly caused by the product.

DISCUSSION

This proof of concept study investigated the influence of latanoprost versus placebo on hair growth and pigmentation in healthy volunteers with androgenetic alopecia. Differences in favor of latanoprost could be seen in the clinical evaluation from 12 weeks of treatment onward ($n = 3$), and in 50% of the study population ($n = 8$) at 24 weeks. The differences concerned hair density, associated with increased hair pigmentation ($n = 4$) and thickness ($n = 3$).

The investigational sites differed in hair density from 8 weeks onward. At 24 weeks at the latanoprost-treated site, the density (+22% in the entire study population) was significantly higher compared with baseline and placebo. As vellus hairs

increased on both investigational sites, the vehicle may also have stimulated hair growth. This has also been reported in topical minoxidil studies.²³ Still, the increase on the placebo-treated site was nonsignificant (1.2%, $P = .3$) compared with the latanoprost-treated site (3.5%, $P = .05$).

The stabile anagen/telogen ratio might indicate that latanoprost does not modify the length of anagen and telogen phases of individual hair follicles. However, as the absolute number of both anagen and telogen hairs increased, it seems latanoprost recruits new hairs into the growth phase.

As each subject acted as his own control and the investigational sites were comparable, the presence of allocation bias can be excluded. Nevertheless, this study had limitations. Only relatively young men with early-stage androgenetic alopecia were included. In an earlier study,²⁴ finasteride-treated vertex and superior-frontal areas showed visible and significant improvement in hair density, whereas no significant differences were observed in the finasteride-treated temporal and anterior hairline areas. Placing the investigational minizones on the frontotemporal regions may thus have affected the results, but underscores the clinical relevance of the hair growth induction capacities of latanoprost.

Because of the interference of hair shafts and background skin, analyzable differences in hair and scalp pigmentation could not be detected using colorimetry. The analysis therefore relied mainly on visual evaluation.

Because of the hair dye, both terminal and vellus hairs are captured with TrichoScan (Tricholog

GmbH). The results may not be directly comparable with studies where methods without dye enhancement (eg, phototrichogram) were used. However, validation studies have shown the good reliability of TrichoScan (Tricholog GmbH),¹⁹ which, together with other dye-enhanced phototrichograms (eg, Canfield technology) are used as gold standard for hair studies and have replaced other techniques.^{25,26} Despite the limitations, this study provides important information about the positive effects of latanoprost on hair growth, and might support the approach to use prostaglandin analogues as a new class of molecules for recruitment of vellus hair follicles and improvement of alopecia.

The erythema observed at the latanoprost-treated site in 5 subjects indicates that the selected concentration is close to the maximum recommendable dose. It must be noted that all subjects with erythema responded well to latanoprost. The skin irritation may have affected the hair growth, however as a result of the short duration of the study this is unlikely.

CONCLUSION

In this pilot study, latanoprost significantly increased overall hair density and the number of vellus and terminal hairs compared with baseline and the placebo-treated area after 8 weeks of topical treatment. This suggests that latanoprost could be useful for treating androgenetic alopecia. More research is needed to determine the optimal dose and treatment duration of latanoprost or other candidate prostaglandin analogues.

REFERENCES

- Alm A, Grierson I, Shields MB. Side effects associated with prostaglandin analog therapy. *Surv Ophthalmol* 2008;53:S93-S195.
- Costagliola C, Del Prete A, Verolino M, Antinozzi P, Fusco R, Parmeggiani F, et al. Effect of 0.005% latanoprost once daily on intraocular pressure in glaucomatous patients not adequately controlled by beta-blockers twice daily: a 3-year follow-up. *Graefes Arch Clin Exp Ophthalmol* 2002;240:379-86.
- Chiba T, Kashiwagi K, Ishijima K, Furuichi M, Kogure S, Abe K, et al. A prospective study of iridial pigmentation and eyelash changes due to ophthalmic treatment with latanoprost. *Jpn J Ophthalmol* 2004;48:141-7.
- Chou S-Y, Chou C-K, Kuang T-M, Hsu W-M. Incidence and severity of iris pigmentation on latanoprost-treated glaucoma eyes. *Eye* 2005;19:784-7.
- Herndon LW, Williams RD, Wand M, Asrani S. Increased periocular pigmentation with ocular hypotensive lipid use in African Americans. *Am J Ophthalmol* 2003;135:713-5.
- Kook MS, Lee K. Increased eyelid pigmentation associated with use of latanoprost. *Am J Ophthalmol* 2000;129:804-6.
- Chien KH, Lu DW, Chen JT. Extensive facial skin pigmentation after latanoprost treatment. *Cutan Ocul Toxicol* 2009;28:185-7.
- Demitsu T, Manabe M, Harima N, Sugiyama T, Yoneda T, Yamada N. Hypertrichosis induced by latanoprost. *J Am Acad Dermatol* 2001;44:721-3.
- Johnstone MA, Albert DM. Prostaglandin-induced hair growth. *Surv Ophthalmol* 2002;47:S185-202.
- Johnstone MA. Hypertrichosis and increased pigmentation of eyelashes and adjacent hair in the region of the ipsilateral eyelids of patients treated with unilateral topical latanoprost. *Am J Ophthalmol* 1997;124:544-7.
- Casson RJ, Selva D. Lash ptosis caused by latanoprost. *Am J Ophthalmol* 2005;139:932-3.
- Mehta JS, Raman J, Gupta N, Thoung D. Cutaneous latanoprost in the treatment of alopecia areata. *Eye* 2003;17:444-6.
- Mansberger SL, Cioffi GA. Eyelash formation secondary to latanoprost treatment in a patient with alopecia. *Arch Ophthalmol* 2000;118:718-9.
- Coronel-Pérez IM, Rodríguez-Rey EM, Camacho-Martínez FM. Latanoprost in the treatment of eyelash alopecia in alopecia areata universalis. *J Eur Acad Dermatol Venereol* 2010;24:481-5.
- Uno H, Zimbric ML, Albert DM, Stjernschantz J. Effect of latanoprost on hair growth in the bald scalp of the stump-tailed macaque: a pilot study. *Acta Derm Venereol* 2002;82:7-12.
- Sasaki S, Hozumi Y, Kondo S. Influence of prostaglandin F_{2α} and its analogues on hair regrowth and follicular melanogenesis in a murine model. *Ext Dermatol* 2005;14:323-8.
- Wolf R, Matz H, Zillich M, Pollack A, Orion E. Prostaglandin analogs for hair growth: great expectations. *Dermatol Online* 2003;9:7.
- Thibaut S, De Becker E, Caisey L, Baras D, Karatas S, Jammayrac O, et al. Human eyelash characterization. *Br J Dermatol* 2010;162:304-10.
- Gassmueller J, Rowold E, Frase T, Hughes-Formella B. Validation of TrichoScan technology as a fully-automated tool for evaluation of hair growth parameters. *Eur J Dermatol* 2009;19:224-31.
- Hoffmann R. TrichoScan: Ein neues Werkzeug für die digitale Haarzählung. *Hautarzt* 2002;53:798-804.
- Hoffmann R. TrichoScan: what is new? *Dermatology* 2005;211:54-62.
- Hoffmann R. TrichoScan: combined epiluminescence microscopy with digital image analysis for the measurement of hair growth in vivo. *Eur J Dermatol* 2001;11:362-8.
- Olsen EA, Whiting D, Bergfeld W, Miller J, Hordinsky M, Wanser R, et al. A multicenter, randomized, placebo-controlled, double-blind clinical trial of a novel formulation of 5% minoxidil topical foam versus placebo in the treatment of androgenetic alopecia in men. *J Am Acad Dermatol* 2007;57:767-74.
- Stough DB, Rao NA, Kaufman KD, Mitchell C. Finasteride improves male pattern hair loss in a randomized study in identical twins. *Eur J Dermatol* 2002;12:32-7.
- Blume-Peytavi U, Kunte C, Krisp A, Garcia Bartels N, Ellwanger U, Hoffmann R. Comparison of the efficacy and safety of topical minoxidil and topical alfatradiol in the treatment of androgenetic alopecia in women. *J Dtsch Dermatol Ges* 2007;5:391-5.
- Blume-Peytavi U, Hillmann K, Dietz E, Canfield D, Garcia Bartels N. A randomized, single-blind trial of 5% minoxidil foam once daily versus 2% minoxidil solution twice daily in the treatment of androgenetic alopecia in women. *J Am Acad Dermatol* 2011 doi: 10.1016/j.jaad.2010.09.724. Published online June 24, 2011.