

# A hypothetical pathogenesis model for androgenic alopecia: clarifying the dihydrotestosterone paradox and rate-limiting recovery factors

Robert S. English Jr.<sup>\*</sup>

*Economics, University of California, Berkeley, United States*

## ABSTRACT

Androgenic alopecia, also known as pattern hair loss, is a chronic progressive condition that affects 80% of men and 50% of women throughout a lifetime. But despite its prevalence and extensive study, a coherent pathology model describing androgenic alopecia's precursors, biological step-processes, and physiological responses does not yet exist. While consensus is that androgenic alopecia is genetic and androgen-mediated by dihydrotestosterone, questions remain regarding dihydrotestosterone's exact role in androgenic alopecia onset. What causes dihydrotestosterone to increase in androgenic alopecia-prone tissues? By which mechanisms does dihydrotestosterone miniaturize androgenic alopecia-prone hair follicles? Why is dihydrotestosterone also associated with hair growth in secondary body and facial hair? Why does castration (which decreases androgen production by 95%) stop pattern hair loss, but not fully reverse it? Is there a relationship between dihydrotestosterone and tissue remodeling observed alongside androgenic alopecia onset?

We review evidence supporting and challenging dihydrotestosterone's causal relationship with androgenic alopecia, then propose an evidence-based pathogenesis model that attempts to answer the above questions, account for additionally-suspected androgenic alopecia mediators, identify rate-limiting recovery factors, and elucidate better treatment targets. The hypothesis argues that: (1) chronic scalp tension transmitted from the galea aponeurotica induces an inflammatory response in androgenic alopecia-prone tissues; (2) dihydrotestosterone increases in androgenic alopecia-prone tissues as part of this inflammatory response; and (3) dihydrotestosterone does not directly miniaturize hair follicles. Rather, dihydrotestosterone is a co-mediator of tissue dermal sheath thickening, perifollicular fibrosis, and calcification – three chronic, progressive conditions concomitant with androgenic alopecia progression. These conditions remodel androgenic alopecia-prone tissues – restricting follicle growth space, oxygen, and nutrient supply – leading to the slow, persistent hair follicle miniaturization characterized in androgenic alopecia.

If true, this hypothetical model explains the mechanisms by which dihydrotestosterone miniaturizes androgenic alopecia-prone hair follicles, describes a rationale for androgenic alopecia progression and patterning, makes sense of dihydrotestosterone's paradoxical role in hair loss and hair growth, and identifies targets to further improve androgenic alopecia recovery rates: fibrosis, calcification, and chronic scalp tension.

## Introduction

Androgenic alopecia (AGA) is characterized as persistent, progressive, patterned hair thinning in scalp regions above the galea aponeurotica (GA) – the dense fibrous membrane underlying AGA-prone hair follicles. It is a common cosmetic complaint and perceived by many sufferers as a “moderately stressful condition that diminishes body image satisfaction” [1]. But despite its prevalence and emotional impact, no viable cure for AGA exists.

While the pathogenesis of AGA is still debated, general consensus is that AGA is androgen- and genetically-mediated, and that

dihydrotestosterone (DHT) – a metabolite of testosterone – plays a causal role in its development [2,3]. In dermal papilla (DP) cells and tissues surrounding AGA-prone hair follicles, DHT attaches to an androgen receptor (AR) after its conversion from free testosterone via the type II 5-alpha reductase enzyme (5-αR2) [4]. As DHT accumulates in androgen-sensitive AGA tissues, AGA-prone hair follicles become sensitive to DHT and start to miniaturize, resulting in hair thinning and eventually AGA.

Pre-pubertal castrates experience a permanent 95% reduction in endogenous androgen production versus non-castrates, and observationally, never develop AGA later in life [5]. AGA can be

<sup>\*</sup> Address: 180 Steuart St, P.O. #193606, San Francisco, CA 94105, United States.  
E-mail address: [rob@perfecthairhealth.com](mailto:rob@perfecthairhealth.com).

stimulated in castrates using a series of testosterone injections [6]. Balding scalp tissues also express higher DHT than non-balding hair-bearing scalp tissues from the same male [7], and males born with a genetic deficiency in 5- $\alpha$ R2 never develop AGA [8]. Accordingly, AGA treatments often target to reduce DHT, specifically by inhibiting 5- $\alpha$ R2.

#### *AGA treatment with 5- $\alpha$ R2 inhibitors: response rate and degree of hair regrowth*

A commonly prescribed FDA-approved drug for AGA management is finasteride, which reduces systemic DHT levels by inhibiting 5- $\alpha$ R2. Daily dosages of 0.2–5.0 mg reduce serum DHT and scalp tissue DHT by roughly 70% and 50–70%, respectively [9].

If response rate is defined as any improvement to hair thinning (slowed progression, arrest, or reversal), clinical studies suggest a response rate to finasteride of 80–90% [10]. However, efficacy appears primarily limited to stopping AGA progression along with a 10% increase in hair count and some hair thickening in thinning regions [11]. Castrate observations imply that even permanent androgen suppression only prevents AGA or stops its progression, but does not regrow all lost hair [5]. The absence of full AGA recoveries from androgen inhibition is puzzling, and highlights the necessity to reevaluate AGA pathology consensus.

#### *Unanswered questions in AGA pathology*

Current AGA pathogenesis models presume genetic influence as the reason why DHT begins to accumulate in AGA-prone scalp tissues. Genes are certainly a factor, as DHT accumulation and follicle sensitivity appear partly genetically determined, with AR density and AR coactivator activity in AGA-prone sites associated with genes shared among AGA sufferers [2,12–14]. However, genetically identical twins demonstrate that while AGA has a genetic predisposition [15], one male twin can bald significantly faster than his counterpart [16], implying genes do not explain all unanswered questions in AGA pathology, and that at a minimum, epigenetics may also play a role.

If AGA-prone hair follicles are genetically programmed to sensitize to and miniaturize in the presence of DHT, then why doesn't complete DHT attenuation lead to complete AGA recovery? If AGA incidence increases with age, why is AGA more common in elderly persons with relatively lower androgen production [7,17,18]? Paradoxically, why is DHT associated with both AGA-prone hair follicle miniaturization and secondary body and facial hair growth [19,20]? Why is AGA mostly isolated to regions above and immediately surrounding the GA?

These questions imply a site-specific, rate-limiting factor to AGA recovery unaddressed by androgen suppression. Some investigators suggest miniaturized hair follicles may suffer from a defect that prevents their conversion from stem cells to progenitor cells [21]. Others imply a relationship between AGA progression and the deterioration of the arrector pili muscle (APM), and that once an APM degenerates to the point of detachment from a hair follicle unit, hair loss may be permanent [22]. But while these findings suggest rate-limiting recovery steps, they do not explain the pathogenesis or mechanisms governing why follicle stem cell to progenitor cell conversion fails, or why an APM detaches from a hair follicle unit.

#### *Unaccounted pathobiological suspects*

Since the discovery of DHT's involvement in AGA, several pro-inflammatory pathways, molecules, cytokines, signaling proteins, and fatty acid derivatives are now suspected to play a role in AGA pathology – observed alongside several chronic scalp symptoms and conditions concurrent with AGA onset [23]. Current AGA pathology models do not explain a relationship between androgens and these pathobiological suspects, nor do they explore if these observed conditions are more causative than associative to hair follicle miniaturization.

This suggests the need for an alternative, evidence-based model for AGA pathogenesis. Such a model must (1) clarify DHT's role in AGA, (2) offer a mechanism behind the rate-limiting effects of androgen suppression in hair regrowth, and (3) explain the roles and relationships of other biomarkers observed in balding scalp tissues.

#### **Hypothesis**

The hypothesis argues that AGA is the result of chronic scalp tension mediated by pubertal and post-pubertal skull bone growth and/or the overdevelopment and chronic contraction of muscles connected to the GA. This leads to a site-specific, pro-inflammatory cascade in GA-fused tissues – upregulating signaling proteins and androgens involved in fibrosis and calcification pathogenesis. This results in slow, persistent tissue remodeling – which restricts follicle growth space and reduces oxygen and nutrient supply to AGA tissues – leading to hair follicle miniaturization and eventually pattern baldness.

#### **Evaluation of hypothesis**

We take an investigative approach to building the pathology model – first cataloguing differences in balding versus non-balding AGA scalps, then exploring association or causation between variables. We start with the physiological responses that develop alongside AGA (i.e., fibrosis) and work backwards to compare their pathobiology against AGA biomarkers (Table 1).

#### *Is fibrosis associative or causative in AGA?*

Collagen deposition in the form of dermal sheath thickening and perifollicular fibrosis is involved in AGA pathology [23,24], but studies have yet to demonstrate direct causality. To determine causality, we must expand our scope to diseases related to collagen overproduction.

This is best documented in scleroderma, a disease characterized by an overproduction of collagen (fibrosis) in cutaneous tissues [25] (i.e., hands, arms, legs, lungs, and scalp skin) [26]. Scleroderma onset in the dermis and epidermis leads to hair loss due to tissue degradation – similar to hair loss after scarring from an acute injury [27]. One case study found that scleroderma in dermal and epidermal scalp tissues leads to scalp hair loss [28].

This suggests dermal sheath thickening and perifollicular fibrosis may be causative rather than associative to hair thinning, but by which mechanisms? The earliest signs of fibrosis in scleroderma patients appear in the areas of severest vascular perturbation [29]. Liver fibrosis pathogenesis models demonstrate that excessive extracellular matrix synthesis and deposition lead to hepatic microvascular and nutritive degradation [30] – potentiating that decreased oxygen and nutrient supply are consequences of fibrosis progression.

Extrapolating to AGA, excessive extracellular matrix deposition may also contribute to tissue vascularity changes in balding scalps. If true, fibrosis onset in AGA offers an explanation as to why balding scalp sites have 40% lower cutaneous oxygen levels vs. non-AGA controls [31], and suggests that fibrosis contributes to follicle miniaturization by reducing oxygen and nutrient supply to AGA tissues – degrading tissue integrity. This is supported by AGA treatments that increase cutaneous blood flow, and consequently improve hair growth [32,33].

Perifollicular fibrosis may also impose physical constrictions to the maximum diametrical length in which a hair follicle can grow – forcing the production of continuously thinner hairs. These fibrotic-driven effects – microvascular insufficiency and follicle spatial constriction – may explain the mechanisms by which fibrosis contributes to AGA.

#### *Re-examining calcification in AGA*

Calcified arterial pathways also show decreased blood flow and oxygen transport [34]. If there is truth to the anecdotes of calcification

**Table 1**  
Summary of observations concomitant with pattern hair loss in AGA tissues.

Domain	Observation	Biomarkers	Evidence
Biological	Androgens	Androgen activity (5- $\alpha$ R2, AR, DHT)	AGA tissues express more 5- $\alpha$ R2 activity, AR activation, and DHT than non-AGA hair-bearing scalp tissues [7,97,98]. Observations of castrates and 5- $\alpha$ R2 deficient men suggest androgen activity is involved in AGA development
	Inflammation	Substances and signaling proteins (ROS, TGF- $\beta$ 1, IL-1 $\alpha$ , IL-1 $\beta$ , TNF- $\alpha$ )	AGA tissues express higher activity of reactive oxygen species (ROS) [99]. ROS tends to increase in the presence of transforming growth factor beta 1 (TGF- $\beta$ 1), an androgen-mediated signaling protein expressed more highly in AGA-affected skin [59,100]. Elevated cytokines such as interleukin 1 alpha (IL-1 $\alpha$ ), interleukin 1 beta (IL-1 $\beta$ ), and tumor necrosis factor alpha (TNF- $\alpha$ ) may contribute to hair loss disorders such as alopecia areata [101,102], are suspected to partially mediate hair cycling from anagen to catagen, and may also contribute to AGA [103–105]
		Prostaglandins (PGD2)	Inflammatory prostaglandins are observed in AGA [23], particularly prostaglandin D2 (PGD2) [106]. PGD2 is elevated in human AGA tissues and inhibits hair lengthening in mice.
		Microorganisms and byproducts ( <i>P. acnes</i> , porphyrins)	One study observed porphyrins in 58% of pilosebaceous canals in those with AGA versus 12% in non-AGA controls [107]. Porphyrins are a byproduct of <i>Propionibacterium acnes</i> ( <i>P. acnes</i> ), a commensal microorganism found in the skin biome which colonize sebaceous ducts, ingests sebum, and are implicated in acute inflammation and acne onset [108]
Physiological	Tissue remodeling	Fibrosis (perifollicular fibrosis, dermal sheath thickening)	Fibrosis develops concurrently with AGA. Studies have found that 37% of AGA sufferers showed significant inflammation and fibrosis surrounding thinning hair follicles (perifollicular fibrosis) [109], increased collagen deposition below AGA miniaturizing follicles [110], and a 2- to 2.5-fold enlargement of the follicle dermal sheath made up of dense collagen bundles [111]. Balding vertex and temple regions have a near 4-fold increase in collagen fibers, [112] and AGA-linked fibrosis may match AGA progression and patterning [67]
		Blood vessel calcification	Autopsy anecdotes suggest that calcification of the capillary networks supporting AGA-affected follicles may coincide with AGA progression. Frederick Hoelzel reported this when removing the brains of cadavers, noting a relationship between capillary calcification and baldness patterning [35]
		Sebaceous gland size	AGA sufferers have enlarged sebaceous glands and higher sebum production in affected hair follicles [77,110,113]
		Vascularity (oxygen)	Transcutaneous oxygen in frontal scalp regions of AGA men is 60% of transcutaneous oxygen in non-AGA counterparts [31], implying microvascular deficiency in AGA tissues
		APM	AGA progression coincides with APM degeneration and its replacement with fat below vellus hair follicles [114]
		Bone (skull shape)	Researchers have noted an anecdotal relationship between skull shape and baldness patterning, even in newborns – whose skull shapes often show similarities to AGA-affected skulls and whose hair often grows in reverse order of AGA patterning as the cranium develops during adolescence [68]
Structural	Tension	GA	Scalp tension in the tissues above the GA appears to match the pattern and progression of AGA where the highest tension points correspond to the first places of AGA onset [57]. This stress may be (1) influenced by androgens, and (2) alter the inactive standby of AR co-activator Hic-5/ARA55 and androgen-mediated TGF $\beta$ -1. A study on a device to relieve scalp tension demonstrated visual hair loss improvements in 65% of patients within 3–12 months [32], implying that GA-related tension may contribute to AGA hair thinning
		Muscular	A pilot study on botulinum toxin injections into the muscles connected to the GA showed an 18% increase in hair count in AGA patients over 48 weeks [74], implying that their chronic contraction may be part of AGA pathology

in capillary networks supporting AGA-affected hair follicles [35], then calcification may be another source of AGA-related microvascular insufficiency. Further investigation is needed, but for purposes of the hypothesis, capillary calcification is included as a potential driver of microvascular insufficiency and thereby contributor to AGA-related hair thinning.

#### Androgen involvement in AGA

Fibrosis and calcification are commonly observed in the arteries of heart disease patients [36] – a disease characterized by the build-up of fats, calcium, and cholesterol in arterial pathways [37,38]. This plaque build-up (atherosclerosis) can lead to arterial fibrosis and arterial calcification [39].

Studies suggest a relationship between AGA and heart disease [40,41], and that early onset AGA may be a predictor for heart disease [42]. On average, cardiovascular disease develops ten years earlier in males than females [43], leading to speculation that androgens may be involved in cardiac disease pathology [44]. Men produce more androgens than women, and on average, have two to threefold higher calcium scores (an evaluation tool for calcification) in coronary arteries

[45]. Bodybuilders who inject exogenous androgens significantly increase their risk of arterial calcification [46]. In mice, dose-dependent DHT and testosterone injections increase arterial calcification lesions by 300–400% [47]. Rats treated with testosterone express increased fibrosis in heart tissues [48].

This implies that AGA-related fibrosis and calcification may be partially androgen-mediated. Since increased 5- $\alpha$ R2, AR, and DHT are all observed in AGA tissues, it's likely this androgen activity precedes fibrosis and calcification in AGA.

Interestingly, *in vitro* studies suggest androgens are uncorrelated or even protective against calcification [48], implying that *in vivo*, androgens interact with unidentified variables to mediate calcification and fibrosis. One study showed that AR-knockout mice produced significantly less arterial calcification after injection with exogenous androgens [48], implying the presence of both androgens and AR as requisites for the mediation of calcification.

Paradoxically, both AGA-affected scalp tissues and hair-bearing body and facial tissues express increased DHT and AR [14,49]. Based on the sustained growth of post-pubertal body and facial hair, these tissues likely don't suffer from the same perifollicular fibrosis, dermal sheath thickening, and calcification seen in AGA. This suggests that in addition

to DHT and AR, there is still a missing variable encouraging the onset of both fibrosis and calcification.

One well-studied mediator of calcification and fibrosis is transforming growth factor beta-1 (TGF- $\beta$ 1) [50,51]. TGF- $\beta$ 1 increases aortic calcification in sheep, potentially as a result of increased alkaline phosphatase activity [52]. TGF- $\beta$ 1 is also suspected to contribute to AGA [53]. Studies conclude that TGF- $\beta$ 1 is an androgen-induced mediator of perifollicular fibrosis [54] and may regulate the hair growth cycle as a negative growth factor [55]. Moreover, scalp DP cells produce higher levels of TGF- $\beta$ 2 than beard DP cells [56].

Further investigation is required to clarify the differences in TGF- $\beta$  expression between secondary facial and body hair tissues versus AGA-affected tissues. However, these findings suggest that (1) TGF- $\beta$  expression is higher in AGA DP cells than secondary facial and body hair DP cells, (2) TGF- $\beta$  mediates calcification and fibrosis in non-AGA tissues, (3) androgen-induced TGF- $\beta$ 1 may induce perifollicular fibrosis, and (4) differences in TGF- $\beta$  expression might explain why AGA-affected hair follicles miniaturize while secondary body and facial hair follicles sustain growth throughout adulthood. This implies that AR, DHT, and TGF- $\beta$ 1 expression are all required for AGA-related tissue remodeling.

#### *Explaining TGF- $\beta$ 1 activation in AGA through mechanotransduction*

If TGF- $\beta$ 1 is androgen-induced, why might TGF- $\beta$ 1 express more highly in AGA tissues versus secondary body and facial hair tissues? Evidence strongly implicates that this is due to mechanical tension.

One study found that mechanical tension from the GA matches the pattern and progression of AGA, with peak tension points corresponding to the first places of hair loss. AGA-prone hair follicles reside within the dermis and subcutaneous fat layers of the scalp, and these layers are fused with the GA as a singular unit. As such, tension from the GA carries into these fused tissues, and thereby AGA-prone hair follicles. The investigators concluded that TGF- $\beta$ 1 expression may result from the tension-mediated induction of the AR coactivator Hic-5/ARA55, and that a “stretch-induced and androgen-mediated mechanotransduction in DP cells could be the primary mechanism in AGA pathogenesis” [57].

Interestingly, TGF- $\beta$ 1 is not only activated by androgenic activity [54], but also by reactive oxygen species (ROS) [58]. ROS are found in AGA-prone tissues, and androgen-induced TGF- $\beta$ 1 in hair follicle DP cells is mediated by ROS [59]. Increased ROS activity may partly explain differences in TGF- $\beta$ 1 expression in body, facial, and AGA-prone follicle tissues.

Mechanical tension can also mediate ROS activity in muscle cells – specifically, muscle stretch [60]. Studies of mechanotransduction (i.e., the mechanisms by which mechanical forces are converted to biological stimuli) demonstrate that mechanical tension in skin, muscle, and bone tissues can alter pro-inflammatory pathways, cytokines, and signaling protein expression [61]. Mechanical tension has also been shown in periodontal tissues to induce cyclooxygenase-2 (COX-2) expression [62], a pathway activated during prostaglandin D2 (PGD2) synthesis. Cell-generated mechanical tension also upregulates TGF- $\beta$  from stiff extracellular matrix [63].

Collectively, these findings highlight the presence of GA-transmitted mechanical tension in AGA onset alongside the induction of ROS, PGD2, and TGF- $\beta$ 1 – all of which are pro-inflammatory substances and overexpressed in balding scalps. This implies that the inflammation observed in AGA is likely tension-mediated, and that GA-transmitted tension may be the starting point of a chronic inflammatory cascade that results in baldness.

Chronic inflammation may, in turn, increase androgen activity. Studies show that DHT modulates the inflammatory response during acute wound healing [64]. In prostate tissues, DHT is shown to exert broad anti-inflammatory effects [65]. One study demonstrated that the pro-inflammatory cytokine interleukin 1 (IL-1) increases androgen

metabolism in chronically inflamed gingivitis tissues and the periodontal ligament [66]. This verifies that androgen activity can be a response to inflammation, and that tension-mediated inflammation may increase DHT, AR, and TGF- $\beta$ 1 in AGA by inducing ROS and other pro-inflammatory biomarkers.

#### *Inducers of GA-transmitted scalp tension*

When evaluating potential drivers of scalp tension, it is important to consider that inflammation observed in AGA tissues is persistent and inversely correlated with the onset of perifollicular fibrosis and dermal sheath thickening [67]. This implies that any factor inducing AGA-related scalp tension (and thereby inflammation) must also be chronic. We hypothesize two androgen-mediated contributors.

The first is pubertal and post-pubertal skull bone growth. One study postulated a relationship between skull shape and baldness patterning [68], proposing that androgen-mediated skull bone growth [69,70] puts stress on capillary networks connected to AGA-prone hair follicles – leading to reduced blood flow and hair follicle miniaturization. Given that sagittal and coronal cranial sutures influence skull shape, underlie the GA, and fuse during adulthood [71] – GA-transmitted mechanical stress from bone growth may even occur after puberty.

The second possibility is the overdevelopment and/or involuntary chronic contraction of muscles connected to the GA – namely, the frontal, occipital, temporal, and external auricular scalp muscles. Androgens influence muscle growth [72,73], and since most adult males produce significantly more androgens than adult females, androgen activity may encourage the overdevelopment (or chronic contraction) of GA-connected muscles – which pulls the fibrous membrane tight and creates tension that transmits to the hair follicles. This notion is supported by a pilot study which injected botulinum toxins into muscles surrounding the GA – forcing their relaxation and leading to an 18% increase in hair count in AGA patients over 48 weeks [74].

Interestingly, in thyroid-associated orbitopathy, the Mueller muscle is chronically contracted and also found to have increased fibrosis and fat deposition [75] – similar to the tissue changes also observed in AGA-related APM degradation [76]. This suggests tension-mediated inflammation may also result in APM destruction, potentially coinciding with the onset of fibrosis, dermal sheath thickening, and calcification. Additional research is needed to elucidate whether APM degeneration is associative or causative in AGA.

Given androgenic and genetic involvement in sexual dimorphism (i.e., bone and muscle development) and AGA onset, both factors likely play a role in AGA-related scalp tension mediation. This concludes the major step-processes of our pathogenesis model (Fig. 1).

#### *Modeling an androgen-inflammation feedback loop*

AGA sufferers often also present increased sebum, bacterial colonies, and porphyrins in AGA-affected tissues. Studies on androgen insensitive subjects imply that androgens regulate sebum production [77]. Commensal bacteria like *Propionibacterium acnes* (*P. acnes*) feed off of sebum [78] and can colonize sebaceous glands with excess sebum production more readily due to an increased food supply. As *P. acnes* metabolizes sebum, it produces porphyrins [79] and “proteins likely to play a role in host-tissue degradation and inflammation” [80] via ROS [81] and the activation of pro-inflammatory cytokines – namely, interleukin 1 alpha (IL-1 $\alpha$ ) and tumor necrosis factor alpha (TNF- $\alpha$ ) [82]. In cases of sebaceous gland over-colonization, *P. acnes* is pathogenic.

Our model suggests that androgen activity increases from tension-mediated inflammation. In this case, the colonization of fungi like dermatophytes [83] or bacteria like *P. acnes* – both of which colonize sebum-rich environments – may create a feedback loop between androgen activity, pathogenic microorganisms, and AGA-related inflammation (Fig. 2).

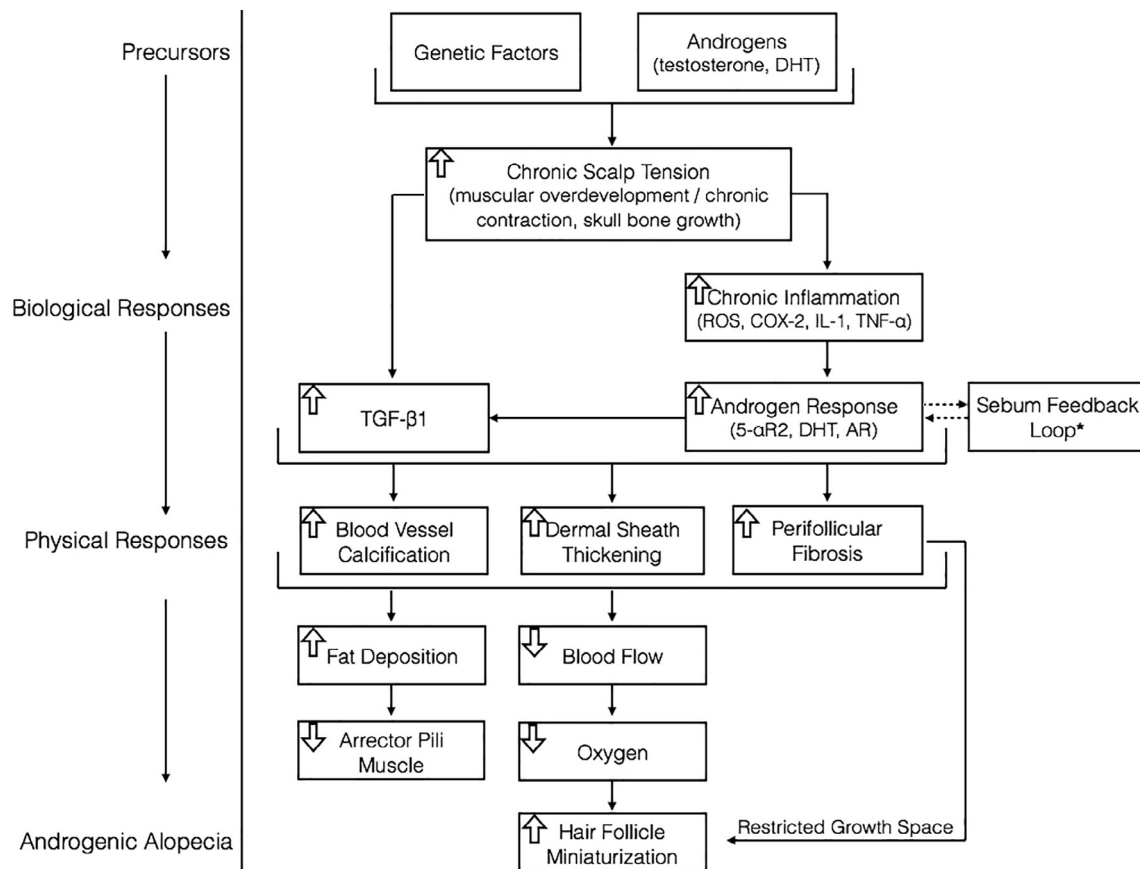


Fig. 1. An illustration visualizing the relationship between AGA's precursors, biological step-processes, and physiological tissue changes that result in hair follicle miniaturization.

#### Explaining donor hair transplant survival rates

Hair transplants (HT) involve the surgical transfer of non-AGA-affected scalp hair follicles from the sides and backs of the scalp to AGA-affected tissues. HT hair count survival rates can exceed 90% one year after surgery [84]. If calcification and fibrosis are the rate-limiting factors to AGA recovery, then why do HT donor hairs not miniaturize? This is answered with the model.

HT surgeries transplant more than just the hair follicle itself. Follicular unit grafts (FUG) procedures transplant “1–4 terminal hair follicles, one (or rarely two) vellus follicles, associated sebaceous lobules, insertion of erector pili muscle, [and the] perifollicular neurovascular network” [85]. Follicular unit extraction (FUE) procedures target singular follicles more specifically, typically with a 1 mm punch

[86]. In either case, tissues surrounding each donor hair follicle are also transplanted.

HT donor tissue sites are not above the GA, and are therefore not under the same chronic tension before their transplantation – implying an absence of perifollicular fibrosis or dermal sheath thickening present in AGA-affected tissues. AGA progression is a decades-long process. If most transplanted donor hair follicles survive one year after hair transplantation, it's likely these HT follicles have not yet had enough time under tension exposure for fibrosis or dermal sheath thickening onset, and thereby hair follicle miniaturization.

One study comparing characteristics of transplanted hairs to and from legs and balding scalps found that “the recipient site influences the growth characteristics of transplanted hairs” [87], with “the thickness of the epidermis, dermis, or subcutaneous tissue, blood supply, or other

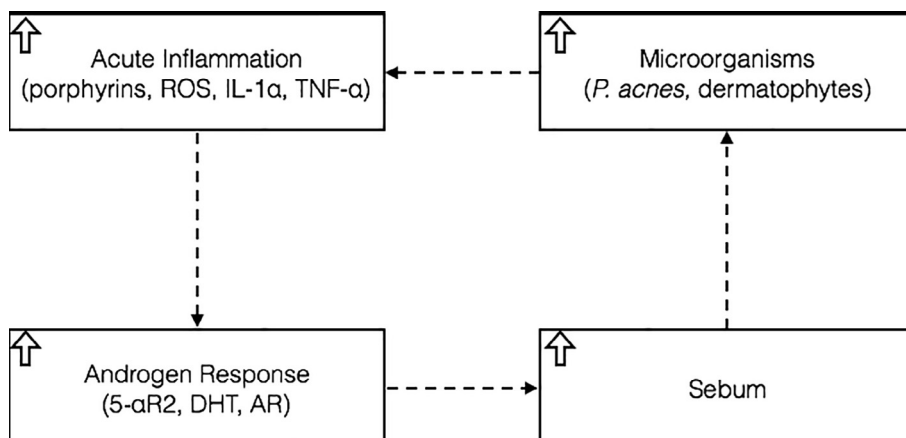


Fig. 2. The Sebum Feedback Loop\* from Fig. 1 – an illustration visualizing a feedback loop between androgen activity, sebum, microorganism colonization, and inflammatory biomarkers observed in AGA tissues.



factors play[ing] a role in survival and growth rate differences.” Another team showed that balding human vellus hair regenerates just as well – and sometimes better – on immunodeficient mice versus terminal human hair [88]. This implies that tissue environment surrounding hair follicles impacts follicle functionality, and that a rate-limiting recovery factor exists in AGA tissues. Therefore, HT success fits in-line with the model, and decades-long studies are still needed to determine the true fate of transplanted donor hairs.

#### *Explaining hair regrowth in estrogen-injected castrates*

While castration appears limited to stopping AGA, observational studies suggest estrogen-injected castrates experience significant hair recovery beyond what is observed from androgen inhibition alone [5]. Similar anecdotes are reported from transsexual male-to-female (MTF) hormone replacement therapy (HRT) recipients, with an undetermined percent experiencing significant hair recovery. From a treatment perspective, estrogen-injected castrates and MTF HRT patients are similar in that both therapies (1) suppress androgen production, and (2) increase estrogen exogenously. If fibrosis and calcification are the rate-limiting recovery factors in AGA, and if DHT inhibition alone is limited to stopping AGA, then why does androgen deprivation alongside estrogen therapy lead to better AGA outcomes than only DHT inhibition? This is also explained by the model.

Androgens and estrogens play dimorphic roles in male and female muscular development [89]. Androgen suppression is an effective strategy to induce muscular atrophy [90]. In MTF HRT patients, exogenous estrogens alongside androgen suppression (drugs or castration) appear to further decrease androgenic activity – and may lead to more muscular atrophy – than androgen suppression alone [91,92]. If these effects extend to the muscles surrounding the GA, then MTF HRT may reduce scalp tension (and thereby AGA-related inflammation) better than androgen suppression by itself, amplifying the effectiveness of DHT-reducing drugs and leading to better AGA recovery in estrogen-injected castrates and MTF HRT patients.

#### **Implications of hypothesis**

We can employ this model to visualize the limitations of current AGA treatments. Finasteride reduces DHT to castrate levels, but its efficacy is typically limited to stopping AGA progression. Our model suggests that DHT attenuation may help prevent fibrosis progression [54], but likely will not reverse fibrosis already present in AGA-affected tissues. FDA-approved minoxidil is purported to increase cutaneous blood flow in AGA tissues [33]. Photo assessments of men applying 5% minoxidil foam twice daily suggest some hair regrowth in 38.4% of participants [93]. However, usage reports suggest that 95% of minoxidil users voluntarily discontinued treatment by 12-months, with 66.5% of withdrawers reporting “low effect” as their rationale [94]. This aligns with our model, which implies that increasing blood flow becomes less effective in treating AGA as fibrosis and calcification progress (Fig. 3).

#### **Suggestions for further research**

##### *Testing the hypothesis*

While the hypothesis attempts to create a more robust AGA pathology model, more research is needed for validation versus the DHT-genetic sensitivity consensus. One challenge is the chicken-egg dilemma. Which came first: the fibrosis and calcification, or the AGA? Anecdotes of AGA-related blood vessel calcification require more investigation. Autopsy studies measuring patients’ pattern and degree of AGA against the pattern and degree of blood vessel calcification supporting AGA tissues and collagen deposition in AGA tissues would help to verify the hypothesis. Long-term studies of subjects from adolescence through adulthood measuring skull bone growth, mechanical tension in

the GA, AGA onset, and DP androgen activity would also serve to test the model. Finally, investigations into signaling protein expression in AGA-prone hair, non-AGA-prone scalp hair, AGA-affected hair, and secondary body and facial hair DP cells may help clarify if interactions beyond DHT and TGF- $\beta$ 1 contribute to the onset of fibrosis and calcification in AGA tissues.

##### *Identifying better AGA treatment targets*

Fibrosis and calcification might be two of the hardest-to-reverse conditions, but recent mechanotransduction studies demonstrate that mechanical offloading may prevent or even partially reverse fibrosis in cutaneous wounds [95,96]. Interestingly, AGA treatments that target scalp tension through mechanical offloading – i.e., botulinum toxin injections in GA-connected muscles or scalp tension relaxer devices – can stop hair loss and result in visible hair regrowth [32,74]. This warrants more investigation into scalp tension as a potential AGA treatment target – and mechanotransduction as a tool to reverse one of AGA’s rate-limiting recovery factors: fibrosis.

#### **Conclusions**

AGA is the result of chronic GA-transmitted scalp tension mediated by pubertal and post-pubertal skull bone growth and/or the over-development and chronic contraction of muscles connected to the GA. This tension induces a pro-inflammatory cascade (increased ROS, COX-2 signaling, IL-1, TNF- $\alpha$ , etc.) which induces TGF- $\beta$ 1 alongside increased androgen activity (5- $\alpha$ R2, DHT, and AR), which furthers TGF- $\beta$ 1 expression in already-inflamed AGA-prone tissues. The concomitant presence of DHT and TGF- $\beta$ 1 mediates perifollicular fibrosis, dermal sheath thickening, and calcification of the capillary networks supporting AGA-prone hair follicles. These chronic, progressive conditions are the rate-limiting factors in AGA recovery. They restrict follicle growth space and decrease oxygen and nutrient supply to AGA-prone tissues – leading to tissue degradation, hair follicle miniaturization, and eventually pattern baldness.

This model allows for genetic influence during any step-process, but refutes the belief that AGA-prone follicles are genetically programmed to become sensitive to DHT. Rather, the model implies that AGA-prone tissues are predisposed to respond to chronic tension-mediated inflammation by inducing DHT and androgen-mediated TGF- $\beta$ 1, which restructure tissue – of which a symptom is hair loss. The model also provides a rationale for unexplained phenomena in AGA pathology, such as:

- Why DHT increases in AGA-prone scalp tissues (i.e., DHT is a response to tension-mediated inflammation)
- The mechanisms by which DHT is involved in AGA progression (i.e., DHT is involved in the onset of fibrosis and calcification)
- The pattern of AGA (i.e., AGA progression matches that of where GA-transmitted scalp tension is highest, and progresses as peak tension points change during fibrosis onset)
- Why AGA is observed more often in elderly populations versus young adults (i.e., calcification and fibrosis have had more time to accumulate)
- Why DHT is associated with body and facial hair growth and also AGA-related hair loss (i.e., tension-mediated inflammation induces TGF- $\beta$ 1 and DHT, and remodels tissue in AGA sites – a phenomenon not observed in body and facial hair growth sites)
- Why androgen suppression stops AGA, but does not regrow all hair (i.e.; DHT inhibitors may reduce fibrosis progression in AGA, but do not reverse fibrosis already present)

Future AGA research should focus on utilizing mechanotransduction to potentially reverse AGA-related tissue remodeling. If the model holds true, then reversing AGA tissue remodeling – rather than attenuating it

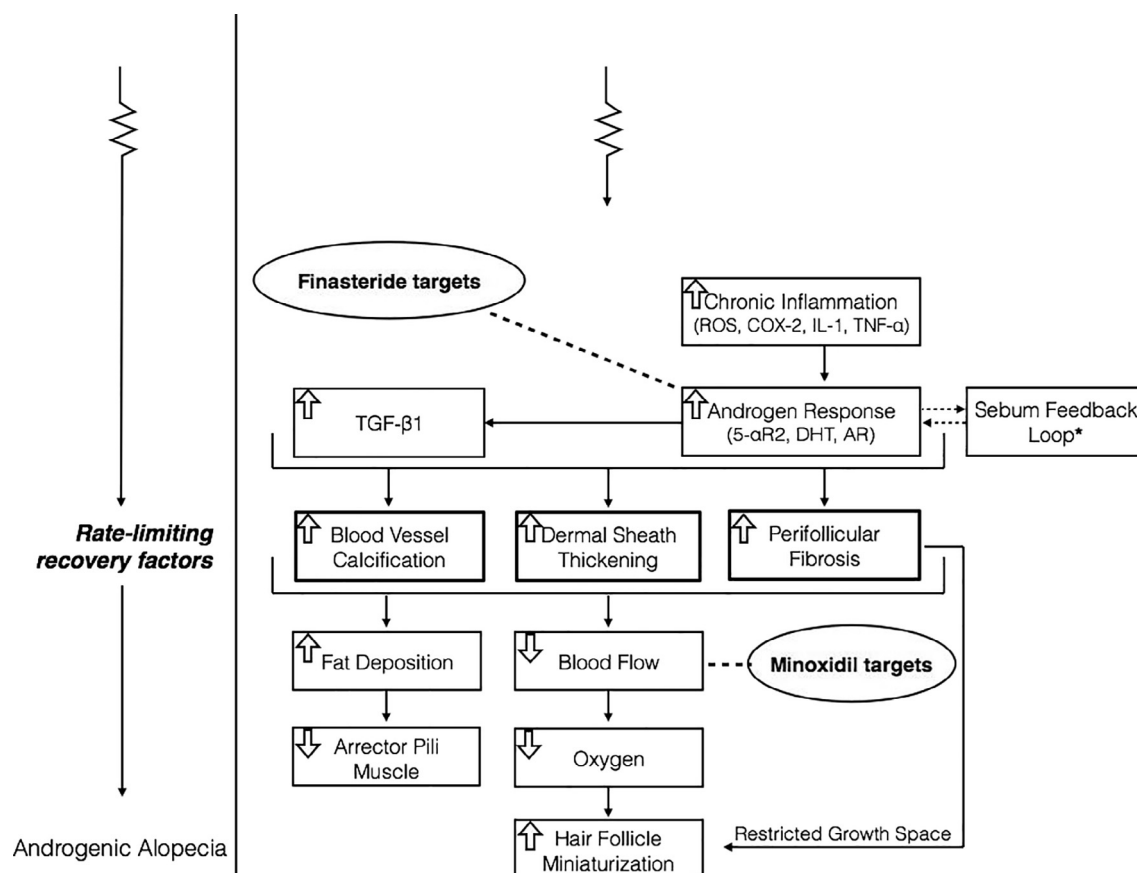


Fig. 3. An illustration to visualize the limitations of FDA-approved AGA treatment drugs within the context of the hypothetical AGA pathology model.

– may pave the pathway to full AGA recoveries.

### Conflict of interest statement

The author declares no conflicts of interest. The author operates a commercial website which intends to provide education about and services for some of the concepts discussed in this paper.

### Funding

This work was not supported by grants.

### Acknowledgement

The author would like to thank Dr. James Barazesh for his invaluable help and feedback in the preparation of this manuscript.

### References

- [1] T. Cash, The psychosocial consequences of androgenetic alopecia: A review of the research literature, 1999.
- [2] Lolli F, Pallotti F, Rossi A, et al. Androgenetic alopecia: a review. *Endocrine* 2017;57:9–17.
- [3] Sinclair R. Male pattern androgenetic alopecia. *BMJ. British Med J* 1998;317:865–9.
- [4] Yang Y-C, Fu H-C, Wu C-Y, Wei K-T, Huang K-E, Kang H-Y. Androgen receptor accelerates premature senescence of human dermal papilla cells in association with DNA damage. *PLoS One* 2013;8:e79434.
- [5] Hamilton JB. Effect of castration in adolescent and young adult males upon further changes in the proportions of bare and hairy scalp\*. *J Clin Endocrinol Metabol* 1960;20:1309–18.
- [6] Kaufman KD. Androgen metabolism as it affects hair growth in androgenetic alopecia. *Dermatol Clin* 1996;14:697–711.
- [7] Schweikert HU, Wilson JD. Regulation of human hair growth by steroid hormones. I. Testosterone metabolism in isolated hairs. *J Clin Endocrinol Metabol* 1974;38:811–9.
- [8] Imperato-McGinley J, Guerrero L, Gautier T, Peterson RE. Steroid 5α-reductase deficiency in man: an inherited form of male pseudohermaphroditism. *Science* 1974;186:1213–5.
- [9] L. Drake, M. Hordinsky, V. Fiedler, et al., The effects of finasteride on scalp skin and serum androgen levels in men with androgenetic alopecia, *Journal of the American Academy of Dermatology*, 41, pp. 550–554.
- [10] Kaufman KD, Rotonda J, Shah AK, Meehan AG. Long-term treatment with finasteride 1 mg decreases the likelihood of developing further visible hair loss in men with androgenetic alopecia (male pattern hair loss). *Eur J Dermatol* 2008;18:400–6.
- [11] K.D. Kaufman, E.A. Olsen, D. Whiting, et al., Finasteride in the treatment of men with androgenetic alopecia, *Journal of the American Academy of Dermatology*, 39, pp. 578–589.
- [12] J.A. Ellis, M. Stebbing and S.B. Harrap, Polymorphism of the Androgen Receptor Gene is Associated with Male Pattern Baldness, *Journal of Investigative Dermatology*, 116, pp. 452–455.
- [13] Heilmann-Heimbach S, Hochfeld LM, Paus R, Nöthen MM. Hunting the genes in male-pattern alopecia: how important are they, how close are we and what will they tell us? *Exp Dermatol* 2016;25:251–7.
- [14] S. Inui and S. Itami, Molecular basis of androgenetic alopecia: From androgen to paracrine mediators through dermal papilla, *Journal of Dermatological Science*, 61, pp. 1–6.
- [15] A.C. Heath, D.R. Nyholt, N.A. Gillespie and N.G. Martin, Genetic Basis of Male Pattern Baldness, *Journal of Investigative Dermatology*, 121, pp. 1561–1564.
- [16] Koyama T, Kobayashi K, Wakisaka N, et al. Eleven pairs of Japanese male twins suggest the role of epigenetic differences in androgenetic alopecia. *Eur J Dermatol* 2013;23:113–5.
- [17] Urysiak-Czubatka I, Kmieć ML, Broniarczyk-Dyła G. Assessment of the usefulness of dihydrotestosterone in the diagnostics of patients with androgenetic alopecia. *Adv Dermatol Allergology/Postepy Dermatologii i Alergologii* 2014;31:207–15.
- [18] Knussmann R, Christiansen K, Kannmacher J. Relations between sex hormone level and characters of hair and skin in healthy young men. *Am J Phys Anthropol* 1992;88:59–67.
- [19] Thornton M, Laing I, Hamada K, Messenger A, Randall V. Differences in testosterone metabolism by beard and scalp hair follicle dermal papilla cells. *Clin Endocrinol* 1993;39:633–9.
- [20] Randall VA, Hibberts NA, Thornton MJ, et al. The hair follicle: a paradoxical androgen target organ. *Hormone Res Paediatr* 2000;54:243–50.
- [21] Garza LA, Yang C-C, Zhao T, et al. Bald scalp in men with androgenetic alopecia retains hair follicle stem cells but lacks CD200-rich and CD34-positive hair follicle progenitor cells. *J Clin Invest* 2011;121:613–22.
- [22] Sinclair R, Torkamani N, Jones L. Androgenetic alopecia: new insights into the

- pathogenesis and mechanism of hair loss. *Research* 2015;4:585.
- [23] Mahé YF, Michelet JF, Billoni N, et al. Androgenetic alopecia and microinflammation. *Int J Dermatol* 2000;39:576–84.
  - [24] Zinkernagel MS, Trüeb RM. Fibrosing alopecia in a pattern distribution: patterned lichen planopilaris or androgenetic alopecia with a lichenoid tissue reaction pattern? *Arch Dermatol* 2000;136:205–11.
  - [25] Gabrielli A, Avvedimento EV, Krieg T. Scleroderma. *N Engl J Med* 2009;360:1989–2003.
  - [26] Careta MF, Romiti R. Localized scleroderma: clinical spectrum and therapeutic update. *Anais brasileiros de dermatologia* 2015;90:62–73.
  - [27] Rabello FB, Souza CD, Farina JA. Júnior, Update on hypertrophic scar treatment. *Clinics* 2014;69:565–73.
  - [28] Pace C, Ward SE, Pace A. A rare case of frontal linear scleroderma (en coup de sabre) with intra-oral and dental involvement. *Br Dent J* 2010;208:249–50.
  - [29] LeRoy EC. Systemic sclerosis: a vascular perspective. *Rheumatic Dis Clin North Am* 1996;22:675–94.
  - [30] Eipel C, Abshagen K, Vollmar B. Regulation of hepatic blood flow: the hepatic arterial buffer response revisited. *World J Gastroenterol* 2010;16:6046–57.
  - [31] Goldman BE, Fisher DM, Ringle SL. Transcutaneous PO2 of the scalp in male pattern baldness: a new piece to the puzzle. *Plast Reconstr Surg* 1996;97:1109–16.
  - [32] Toshitani S, Nakayama J, Yahata T, Yasuda M, Urabe H. A new apparatus for hair regrowth in male-pattern baldness. *The Journal of dermatology* 1990;17:240–6.
  - [33] Wester RC, Maibach HI, Guy RH, Novak E. Minoxidil stimulates cutaneous blood flow in human balding scalps: pharmacodynamics measured by laser Doppler velocimetry and photopulse plethysmography. *J Invest Dermatol* 1984;82:515–7.
  - [34] Tsuchiya M, Suzuki E, Egawa K, et al. Stiffness and impaired blood flow in lower-leg arteries are associated with severity of coronary artery calcification among asymptomatic type 2 diabetic patients. *Diabetes Care* 2004;27:2409–15.
  - [35] Hoelzel F. Baldness and calcification of the ivory dome. *J Am Med Assoc* 1942;119:968–968.
  - [36] Shao J-S, Sierra OL, Cohen R, et al. Vascular calcification and aortic fibrosis. *Arterioscler Thromb Vasc Biol* 2011;31:1821–33.
  - [37] Travers JG, Kamal FA, Robbins J, Yutzey KE, Blaxall BC. Cardiac fibrosis. *Circ Res* 2016;118:1021–40.
  - [38] Lusis AJ. Atherosclerosis. *Nature* 2000;407:233–41.
  - [39] Mozos I, Malainer C, Horbańczuk J, et al. Inflammatory markers for arterial stiffness in cardiovascular diseases. *Front Immunol* 2017;8.
  - [40] Lotufo PA, Chae CU, Ajani UA, Hennekens CH, Manson JE. Male pattern baldness and coronary heart disease: the Physicians' Health Study. *Arch Intern Med* 2000;160:165–71.
  - [41] Trevisan M, Farinero E, Krogh V, et al. Baldness and coronary heart disease risk factors. *J Clin Epidemiol* 1993;46:1213–8.
  - [42] Sharma KH, Jindal A. Association between androgenetic alopecia and coronary artery disease in young male patients. *Int J Trichol* 2014;6:5.
  - [43] Lorenzo C, Williams K, Hunt KJ, Haffner SM. The national cholesterol education program-adult treatment panel III, International Diabetes Federation, and World Health Organization definitions of the metabolic syndrome as predictors of incident cardiovascular disease and diabetes. *Diabetes care* 2007;30:8–13.
  - [44] Pérez-López FR, Larrad-Mur L, Kallen A, Chedraui P, Taylor HS. Gender differences in cardiovascular disease: hormonal and biochemical influences. *Reproduct Sci* 2010;17:511–31.
  - [45] Makaryus AN, Sison C, Kohansieh M, Makaryus JN. Implications of gender difference in coronary calcification as assessed by CT coronary angiography. *Clinical Medicine Insights. Cardiology* 2014;8:51.
  - [46] Santora LJ, Marin J, Vangrow J, et al. Coronary calcification in body builders using anabolic steroids. *Prevent Cardiol* 2006;9:198–201.
  - [47] McRobb L, Handelsman DJ, Heather AK. Androgen-induced progression of arterial calcification in apolipoprotein e-null mice is uncoupled from plaque growth and lipid levels. *Endocrinology* 2009;150:841–8.
  - [48] Zhu D, Hadoko PWF, Wu J, et al. Ablation of the androgen receptor from vascular smooth muscle cells demonstrates a role for testosterone in vascular calcification 2016;6:24807.
  - [49] Lai J-J, Chang P, Lai K-P, Chen L, Chang C. The role of androgen and androgen receptor in skin-related disorders. *Arch Dermatol Res* 2012;304:499–510.
  - [50] Sime PJ, Xing Z, Graham FL, Csaky KG, Gauldie J. Adenovector-mediated gene transfer of active transforming growth factor-beta1 induces prolonged severe fibrosis in rat lung. *J Clin Invest* 1997;100:768.
  - [51] Roberts AB, Sporn MB, Assoian RK, et al. Transforming growth factor type beta: rapid induction of fibrosis and angiogenesis in vivo and stimulation of collagen formation in vitro. *Proc Natl Acad Sci* 1986;83:4167–71.
  - [52] Clark-Greuel JN, Connolly JM, Sorichillo E, et al. Transforming growth factor-β1 mechanisms in aortic valve calcification: increased alkaline phosphatase and related events. *Ann Thoracic Surgery* 2007;83:946–53.
  - [53] Lomashvili KA, Cobbs S, Hennigar RA, Hardcastle KI, O'Neill WC. Phosphate-induced vascular calcification: role of pyrophosphate and osteopontin. *J Am Soc Nephrol* 2004;15:1392–401.
  - [54] Yoo HG, Kim JS, Lee SR, et al. Perifollicular fibrosis: pathogenetic role in androgenetic alopecia. *Biol Pharm Bull* 2006;29:1246–50.
  - [55] Mori O, Hachisuka H, Sasai Y. Effects of transforming growth factor β1 in the hair cycle. *J Dermatol* 1996;23:89–94.
  - [56] Rutberg SE, Kolpak ML, Gourley JA, Tan G, Henry JP, Shander D. Differences in expression of specific biomarkers distinguish human beard from scalp dermal papilla cells. *J Invest Dermatol* 2006;126:2583–95.
  - [57] Tellez-Segura R. Involvement of mechanical stress in androgenetic alopecia. *Int J Trichol* 2015;7:95.
  - [58] Barcellos-Hoff MH, Dix TA. Redox-mediated activation of latent transforming growth factor-beta 1. *Mol Endocrinol* 1996;10:1077–83.
  - [59] Shin H, Yoo HG, Inui S, et al. Induction of transforming growth factor-beta 1 by androgen is mediated by reactive oxygen species in hair follicle dermal papilla cells. *BMB Rep* 2013;46:460–4.
  - [60] Ward CW, Prosser BL, Lederer WJ. Mechanical stretch-induced activation of ROS/RNS signaling in striated muscle. *Antioxid Redox Signal* 2014;20:929–36.
  - [61] Duschler D, Maan ZN, Wong VW, et al. Mechanotransduction and fibrosis. *J Biomech* 2014;47:1997–2005.
  - [62] Shimizu N, Ozawa Y, Yamaguchi M, Goseki T, Ohzeki K, Abiko Y. Induction of COX-2 expression by mechanical tension force in human periodontal ligament cells. *J Periodontol* 1998;69:670–7.
  - [63] Wells RG, Discher DE. Matrix elasticity, cytoskeletal tension, and TGF-α: the insoluble and soluble meet. *Sci Signal* 2008;1:13.
  - [64] Gilliver SC, Ashworth JJ, Mills SJ, Hardman MJ, Ashcroft GS. Androgens modulate the inflammatory response during acute wound healing. *J Cell Sci* 2006;119:722–32.
  - [65] Vignozzi L, Cellai I, Santi R, et al. Antiinflammatory effect of androgen receptor activation in human benign prostatic hyperplasia cells. *J Endocrinol* 2012;214:31–43.
  - [66] Kasasa SC, Soory M. The effect of interleukin-1 (IL-1) on androgen metabolism in human gingival tissue (HGT) and periodontal ligament (PDL). *J Clin Periodontol* 1996;23:419–24.
  - [67] El-Domyati M, Attia S, Saleh F, Abdel-Wahab H. Androgenetic alopecia in males: a histopathological and ultrastructural study. *J Cosmetic Dermatol* 2009;8:83–91.
  - [68] Taylor PJ. Big head? Bald head! Skull expansion: alternative model for the primary mechanism of AGA. *Med Hypotheses* 2009;72:23–8.
  - [69] Ilangoan R, Sittadjody S, Balaganesh M, et al. Dihydrotestosterone is a determinant of calcaneal bone mineral density in men. *J Steroid Biochem Mole Biol* 2009;117:132–8.
  - [70] Vanderschueren D, Vandenput L, Boonen S, Lindberg MK, Bouillon R, Ohlsson C. Androgens and bone. *Endocr Rev* 2004;25:389–425.
  - [71] Lynnerup N, Jacobsen JC. Brief communication: age and fractal dimensions of human sagittal and coronal sutures. *Am J Phys Anthropol* 2003;121:332–6.
  - [72] Clarke BL, Khosla S. Androgens and bone. *Steroids* 2009;74:296–305.
  - [73] O'Connell MD, Wu FC. Androgen effects on skeletal muscle: implications for the development and management of frailty. *Asian J Androl* 2014;16:203.
  - [74] Freund BJ, Schwartz M. Treatment of Male Pattern Baldness with Botulinum Toxin: A Pilot Study. *Plast Reconstr Surg* 2010;126:246e–8e.
  - [75] Cockerham KP, Hidayat AA, Brown HG, Cockerham GC, Graner SR. Clinicopathologic evaluation of the Mueller muscle in thyroid-associated orbitopathy. *Ophthalmic Plast Reconstr Surg* 2002;18:11–7.
  - [76] Torkamani N, Rufaut NW, Jones L, Sinclair RD. Beyond goosebumps: does the arrector pili muscle have a role in hair loss? *Int J Trichol* 2014;6:88.
  - [77] Imperato-McGinley J, Gautier T, Cai L, Yee B, Epstein J, Pochi P. The androgen control of sebum production. Studies of subjects with dihydrotestosterone deficiency and complete androgen insensitivity. *J Clin Endocrinol Metabol* 1993;76:524–8.
  - [78] Tanghe EA. The role of inflammation in the pathology of acne. *J Clin Aesthetic Dermatol* 2013;6:27.
  - [79] Shu M, Kuo S, Wang Y, et al. Porphyrin metabolisms in human skin commensal *Propionibacterium acnes* bacteria: potential application to monitor human radiation risk. *Curr Med Chem* 2013;20:562–8.
  - [80] Holland C, Mak TN, Zimny-Arndt U, et al. Proteomic identification of secreted proteins of *Propionibacterium acnes*. *BMC Microbiol* 2010;10:230.
  - [81] Arican O, Kurutas EB, Sasmaz S. Oxidative stress in patients with acne vulgaris. *Mediators Inflamm* 2005;2005:380–4.
  - [82] Lee SE, Kim J-M, Jeong SK, et al. Protease-activated receptor-2 mediates the expression of inflammatory cytokines, antimicrobial peptides, and matrix metalloproteinases in keratinocytes in response to *Propionibacterium acnes*. *Arch Dermatol Res* 2010;302:745–56.
  - [83] Sentamilselvi G, Janaki C, Murugusundram S. Trichomycoses. *Int J Trichol* 2009;1:100.
  - [84] Parsley WM, Perez-Meza D. Review of factors affecting the growth and survival of follicular grafts. *J Cutaneous Aesthetic Surgery* 2010;3:69.
  - [85] Khanna M. Hair transplantation surgery. *Indian J Plastic Surgery* 2008;41:S56.
  - [86] Rassman W, Pak J, Kim J. Follicular unit extraction: evolution of a technology. *J Transplant Technol Res* 2016;6. pp. 2161-0991, 1000158.
  - [87] Hwang S, Kim JC, Ryu HS, Cha YC, Lee SJ, Na GY. Does the recipient site influence the hair growth characteristics in hair transplantation? *Dermatol Surg* 2002;28:795–9.
  - [88] Krajcik RA, Vogelmann JH, Malloy VL, Orentreich N. Transplants from balding and hairy androgenetic alopecia scalp regrow hair comparably well on immunodeficient mice. *J Am Acad Dermatol* 2003;48:752–9.
  - [89] Notelovitz M. Androgen effects on bone and muscle. *Fertil Steril* 2002;77:34–41.
  - [90] Cheung AS, Zajac JD, Grossmann M. Muscle and bone effects of androgen deprivation: current and emerging therapies. *Endocrine-Related Cancer* 2014. pp. ERC-14-0172.
  - [91] Kwan M, VanMaasdam J, Davidson JM. Effects of estrogen treatment on sexual behavior in male-to-female transsexuals: experimental and clinical observations. *Arch Sex Behav* 1985;14:29–40.
  - [92] Sripatha B, Adaihan PG. Estrogen and phytoestrogen predispose to erectile dysfunction: do ER-alpha and ER-beta in the cavernosum play a role? *Urology* 2004;63:382–6.
  - [93] Olsen EA, Whiting D, Bergfeld W, et al. A multicenter, randomized, placebo-controlled, double-blind clinical trial of a novel formulation of 5% minoxidil topical foam versus placebo in the treatment of androgenetic alopecia in men. *J Am Acad*



- Dermatol 2007;57:767–74.
- [94] Ali Mapar M, Omidian M. Is topical minoxidil solution effective on androgenetic alopecia in routine daily practice? *J Dermatol Treatment* 2007;18:268–70.
- [95] Gurtner GC, Dauskardt RH, Wong VW, et al. Improving cutaneous scar formation by controlling the mechanical environment: large animal and phase I studies. *Ann Surg* 2011;254:217–25.
- [96] Lim AF, Weintraub J, Kaplan EN, et al. The embrace device significantly decreases scarring following scar revision surgery in a randomized controlled trial. *Plast Reconstr Surg* 2014;133:398.
- [97] Sawaya ME, Price VH. Different levels of 5 $\alpha$ -reductase type I and II, aromatase, and androgen receptor in hair follicles of women and men with androgenetic alopecia. *J Invest Dermatol* 1997;109:296–300.
- [98] Hibberts N, Howell A, Randall V. Balding hair follicle dermal papilla cells contain higher levels of androgen receptors than those from non-balding scalp. *J Endocrinol* 1998;156:59–65.
- [99] J.H. Upton, R.F. Hannen, A.W. Bahta, N. Farjo, B. Farjo and M.P. Philpott, Oxidative Stress – associated Senescence in Dermal Papilla Cells of Men with Androgenetic Alopecia, *Journal of Investigative Dermatology*, 135, pp. 1244–1252.
- [100] Gaspar NK. DHEA and frontal fibrosing alopecia: molecular and physiopathological mechanisms. *Anais brasileiros de dermatologia* 2016;91:776–80.
- [101] Rückert R, Lindner G, Bulfone-Paus S, Paus R. High-dose proinflammatory cytokines induce apoptosis of hair bulb keratinocytes in vivo. *Br J Dermatol* 2000;143:1036–9.
- [102] Kasumagic-Halilovic E, Prohic A, Cavaljuga S. Tumor necrosis factor- $\alpha$  in patients with alopecia areata. *Indian J Dermatol* 2011;56:494.
- [103] Messenger A, De Berker D, Sinclair R. Disorders of hair. *Rook's Textbook of Dermatology*: Eighth Edition; 2010. p. 1–100.
- [104] Hoffmann R, Happle R, Paus R. Elements of the interleukin-1 signaling system show hair cycle-dependent gene expression in murine skin. *Eur J Dermatol: EJD* 1997;8:475–7.
- [105] Tong X, Coulombe PA. Keratin 17 modulates hair follicle cycling in a TNF $\alpha$ -dependent fashion. *Genes Dev* 2006;20:1353–64.
- [106] Garza LA, Liu Y, Yang Z, et al. Prostaglandin D2 inhibits hair growth and is elevated in bald scalp of men with androgenetic alopecia. *Sci Trans Med* 2012;4:126ra134.
- [107] Young JW, Conte E, Leavitt M, Nafz M, Schroeter A. Cutaneous immunopathology of androgenetic alopecia. *J Am Osteopathic Assoc* 1991;91:765–71.
- [108] A. Bhatia, J.-F. Maisonneuve and D.H. Persing, *Propionibacterium acnes* and chronic diseases, *The Infectious Etiology of Chronic Diseases: Defining the Relationship, Enhancing the Research, and Mitigating the Effects: Workshop Summary.*, Knobler, SL et al. (eds.) (2004), pp. 74–80.
- [109] Whiting DA. Chronic telogen effluvium: increased scalp hair shedding in middle-aged women. *J Am Acad Dermatol* 1996;35:899–906.
- [110] Lattanand A, Johnson WC. Male pattern alopecia a histopathologic and histochemical study. *J Cutan Pathol* 1975;2:58–70.
- [111] Jaworsky C, Kligman A, Murphy G. Characterization of inflammatory infiltrates in male pattern alopecia: implications for pathogenesis. *Br J Dermatol* 1992;127:239–46.
- [112] Won CH, Kwon OS, Kim YK, et al. Dermal fibrosis in male pattern hair loss: a suggestive implication of mast cells. *Arch Dermatol Res* 2008;300:147–52.
- [113] Kure K, Isago T, Hirayama T. Changes in the sebaceous gland in patients with male pattern hair loss (androgenic alopecia). *J Cosmetic Dermatol* 2015;14:178–84.
- [114] Torkamani N, Rufaut N, Jones L, Sinclair R. Destruction of the arrector pili muscle and fat infiltration in androgenic alopecia. *Br J Dermatol* 2014;170:1291–8.